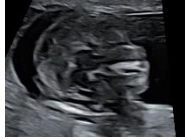

Videos of ultrasonography of normal fetal structures

(I) First trimester

Sagittal view of fetal brain



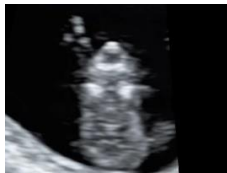Creator: KY Leung, EC, AFSUMB

Duration: 0:24

This clip shows the fetal thalamus, midbrain, brainstem, intracranial translucency, and cisterna magnum.

Published on 6 December 2020. Used with permission

Coronal view of fetal face



Creator: KY Leung, EC, AFSUMB

Duration: 0:12

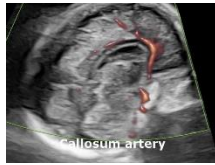This clip shows the retronasal triangle, both orbits, both ears, and mandibular gap.

Published on 6 December 2020. Used with permission

(II) Mid-trimester

Brain

Corpus callosum



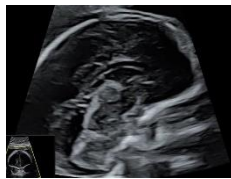Creator: KY Leung, EC, AFSUMB

Duration: 0:14

This clip shows the different views of the fetal corpus callosum: (a) midline sagittal view, (b) color Doppler flow of the pericallosum artery, and three-dimensional (c) multiplanar view and (d) multi-slice view with the volume acquired by the 'corpus callosum' mode.

Published on 6 December 2020. Used with permission

Sagittal view of fetal brain in the mid-trimester



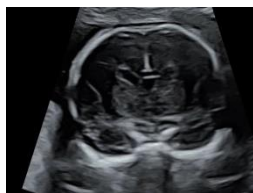Creator: KY Leung, EC, AFSUMB

Duration: 0:24

This clip shows the fetal corpus callosum, cavum septi pellucidi, third ventricle, thalamus, cerebellar vermis and lateral ventricle.

Published on 6 December 2020. Used with permission

Coronal view of fetal brain in the mid-trimester



Creator: KY Leung, EC, AFSUMB

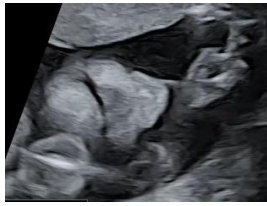
Duration: 0:13

This clip shows the fetal interhemisphere fissure, cavum septi pellucidi, frontal horns, thalami, and occipital horns.

Published on 6 December 2020. Used with permission

Face

Coronal view of the fetal upper lip



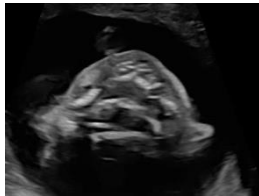
Creator: KY Leung, EC, AFSUMB

Duration: 0:20

This clip shows the coronal view of the upper lip and nose

Published on 21 January 2021. Used with permission

Transverse view of the fetal hard palate



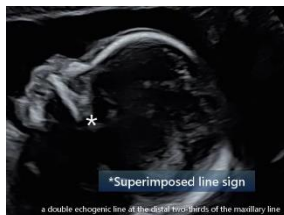Creator: KY Leung, EC, AFSUMB

Duration: 0:10

This clip shows the horizontal plate of the hard palate with a 'flying bat' appearance.

Published on 6 December 2020. Used with permission

Superimposed-line sign



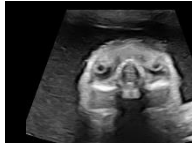Creator: KY Leung, EC, AFSUMB

Duration: 0:52

This clip shows superimposed-line sign: a double echogenic line at the distal two-thirds of the maxillary line

Published on 20 January 2021. Used with permission

Coronal view of the fetal orbits



Creator: KY Leung, EC, AFSUMB

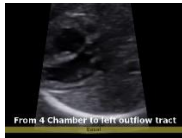Duration: 0:04

This clip shows both orbits with the nose in between, and the movement of both lenses.

Published on 6 December 2020. Used with permission

Heart

Fetal heart: from the basal four-chamber view to the left ventricular outflow tract view



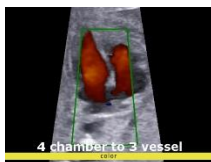
Creator: KY Leung, EC, AFSUMB

Duration: 0:07

This clip shows the fetal heart from the basal four-chamber view to the left ventricular outflow tract view

Published on 6 December 2020. Used with permission

Fetal heart: from the apical four-chamber view to three-vessel trachea view



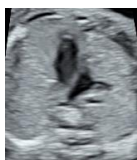Creator: KY Leung, EC, AFSUMB

Duration: 0:16

This clip shows the fetal heart from four-chamber to three-vessel trachea view, and from gray scale imaging to color Doppler flow.

Published on 6 December 2020. Used with permission

Fetal heart: four-chamber view, left ventricular outflow tract, three vessel and trachea view and branches of pulmonary trunk



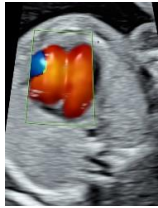Creator: KY Leung, EC, AFSUMB

Duration: 0:33

This clip shows fetal heart: four-chamber, left ventricular outflow tract, three vessel and trachea views, branches of pulmonary trunk into right and left pulmonary arteries.

Published on 14 December 2020. Used with permission

Fetal heart: radiant flow



Creator: KY Leung, EC, AFSUMB

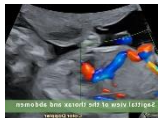Duration: 0:21

This clip shows radiant blood flow in the four-chamber, left outflow tract and three-vessel views

Published on 14 December 2020. Used with permission

Abdomen

Umbilical portal venous system



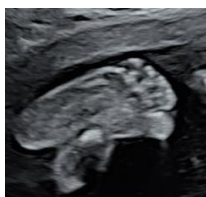
Creator: KY Leung, EC, AFSUMB

Duration: 0:52

This clip shows color Doppler flow of umbilical portal venous system including umbilical vein, ductus venosus, hepatic vein, and inferior vena cava

Published on 24 January 2021. Used with permission

Feet



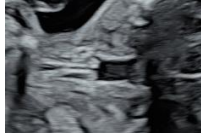Creator: KY Leung, EC, AFSUMB

Duration: 0:14

This clip shows five toes of both feet.

Published on 14 December 2020. Used with permission

Vocal cords: movement



Creator: KY Leung, EC, AFSUMB

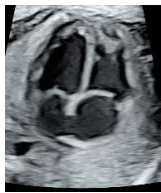Duration: 0:08

This clip shows abduction and adduction of vocal cords

Published on 14 December 2020. Used with permission

(III) Third trimester

Heart



Creator: KY Leung, EC, AFSUMB

Duration: 0:18

This clip shows the four chamber, left ventricular outflow tract and three-vessel views of the fetal heart at 30 weeks' gestation

Published on 14 December 2020. Used with permission